

# Comparative evaluation of crestal bone levels around endosseous implants as influenced by conventional and diode laser during second-stage surgery in mandibular implant-supported overdenture: An *in vivo* study

Sushant Bajaj, Sapna Rani, Gaurav Issar, Upasana Sethi<sup>1</sup>, Shalabh Kumar, Sarvesh Mishra

Departments of Prosthodontics and <sup>1</sup>Oral Medicine and Radiology, ITS-CDSR, Uttar Pradesh, India

## Abstract

**Aim:** This study aims to evaluate and compare the crestal bone levels around implants as influenced by conventional and diode laser during second-stage surgery in an edentulous mandible using cone beam computed tomography (CBCT) and digital radiography (DR).

**Settings and Design:** A split-mouth *in vivo* prospective study on edentulous patients involving placement of two implants in mandible followed by the comparison of two different techniques for second-stage surgery.

**Materials and Methods:** The study was undertaken to evaluate the crestal bone change around 16 implant sites distributed in two groups (eight implants each) following two methods during second-stage surgery, i.e., Group 1 - Conventional second stage and Group 2 - Diode laser. Measurements were made on two sides (mesial and distal) using intraoral periapical and four sides (labial, lingual, mesial, and distal) using CBCT scans for both groups. These measurements were conducted at two time intervals for both, i.e., immediately after implant loading and twenty 4 weeks after implant loading. The values obtained were subjected to statistical analysis.

**Statistical Analysis Used:** The normality of data was checked by Shapiro–Wilk’s test. Intragroup comparison was compared using independent *t*-test by *post hoc* comparison by Bonferroni method ( $P < 0.05$ ).

**Results:** Crestal bone loss at the time of loading for Group 1 evaluated by CBCT was  $0.950 \pm 0.988$  while after 24 weeks of loading, it was  $1.388 \pm 0.576$ . For Group 2, mean crestal bone loss was  $1.200 \pm 0.925$  at the time of loading, and after 24 weeks, it was  $1.512 \pm 0.674$ . Crestal bone loss at the time of loading for Group 1 evaluated by DR was  $1.075 \pm 0.849$  while after 24 weeks of loading, it was  $1.562 \pm 0.480$ . For Group 2, mean crestal bone loss was  $1.162 \pm 0.833$  at the time of loading and after 24 weeks, it was  $1.700 \pm 0.498$ .

**Conclusions:** In the present study, no statistically significant difference was observed in crestal bone loss between conventional and diode laser technique.

**Keywords:** Conventional second stage, crestal bone loss, digital radiography, diode laser

**Address for correspondence:** Dr. Sapna Rani, House No. 2062, Sector 7D, Faridabad, Haryana, India.

E-mail: [drsapnadaksh@gmail.com](mailto:drsapnadaksh@gmail.com)

**Received:** 09<sup>th</sup> February, 2019, **Revision:** 26<sup>th</sup> May, 2019, **Accepted:** 11<sup>th</sup> December, 2019, **Publication:** 27<sup>th</sup> January, 2020

Access this article online	
Quick Response Code:	Website: <a href="http://www.j-ips.org">www.j-ips.org</a>
	DOI: 10.4103/jips.jips_55_19

This is an open access journal, and articles are distributed under the terms of the Creative Commons Attribution-NonCommercial-ShareAlike 4.0 License, which allows others to remix, tweak, and build upon the work non-commercially, as long as appropriate credit is given and the new creations are licensed under the identical terms.

**For reprints contact:** [reprints@medknow.com](mailto:reprints@medknow.com)

**How to cite this article:** Bajaj S, Rani S, Issar G, Sethi U, Kumar S, Mishra S. Comparative evaluation of crestal bone levels around endosseous implants as influenced by conventional and diode laser during second-stage surgery in mandibular implant-supported overdenture: An *in vivo* study. J Indian Prosthodont Soc 2020;20:52-60.

## INTRODUCTION

The goal of modern dentistry is to restore the patient to normal contour, function, comfort, esthetics, speech, and health, whether by removing caries from a tooth or replacing several teeth.<sup>[1]</sup> Loss of teeth has been a part of expected course of ageing. Edentulism still has a high prevalence in the elderly population and is generally considered a common clinical entity.<sup>[2]</sup> The advent of osseointegrated implants has greatly enhanced the treatment outcome in edentulous patients and has been advocated as a predictable and successful therapeutic concept for many decades. According to The McGill and York consensus statements on overdentures, "The evidence currently available suggests that the restoration of the edentulous mandible with a conventional denture is no longer the first choice for prosthodontic treatment. There is now overwhelming evidence that an implant supported overdenture has become the first choice of treatment for the edentulous mandible."<sup>[3,4]</sup>

Crestal bone loss has been a major concern in implantology as it jeopardizes the longevity and success of implant prosthesis.<sup>[5]</sup> Second-stage surgery is often overlooked and is considered nonessential phase but actually could determine the health of the peri-implant tissue.<sup>[6]</sup> The six main factors listed in the literature for crestal bone loss are surgical trauma and healing response, occlusal overload, peri-implantitis, microgap, biologic width, and implant crest module. Loss of alveolar crest height is most commonly documented by measuring the radiographic distance from implant platform to the alveolar crest. Digital radiography (DR) has been used to determine thresholds of change for attachment loss and computer-aided measurements of alveolar crest height and alveolar bone mass.<sup>[7]</sup>

During second stage, uncovering of implant is done by various means. Flap elevation by means of a split-thickness flap has been evaluated in literature.<sup>[8]</sup> Laser has also been advocated for second stage surgery as it allows precise tissue trimming in a bloodless field and also allows control of depth of tissue removal. Different types of dental lasers including diode laser have been used for second-stage implant surgery. They demonstrated safety, ease of use, faster recovery and accelerated start of the restorative phase. Diodes come in different wavelengths, the energy from these lasers target pigments such as hemoglobin and melanin in the soft tissue.<sup>[9,10]</sup> Considering the literature, and availability of various techniques to perform stage two implant surgery, the purpose of this study was an attempt to compare the effect of two most commonly used techniques

for stage two surgery, i.e., conventional and with diode laser on crestal bone levels around root form two piece endosseous implants in an edentulous mandible using cone beam computed tomography (CBCT) and DR. Primary outcome measure of study was assessment of crestal bone level. Secondary outcome measures included assessment of crestal bone level by conventional technique and laser technique at second-stage surgery at mesial, distal, labial, and lingual side of implant.

## MATERIALS AND METHODS

### Subject selection

A total of 10 individuals (males) within the age range of 40–70 years were selected for the study following inclusion and exclusion criteria.

Sample size was determined by formula as follows:

$$n = \frac{(\sigma_1^2 + \sigma_2^2)(Z_{1-\alpha/2} + Z_{1-\beta})^2}{\Delta^2}$$

The notation for the formula is:

$n$  = Sample size of groups  $\sigma_1$  = standard deviation of Group 1

$\sigma_2$  = standard deviation of Group 2

$\Delta$  = difference in group means

$Z_{1-\alpha/2}$  = two-sided Z value  $Z_{1-\beta}$  = power = 80%.

From previous studies values were obtained and put into the formula. Sample size came out to be 10 but out of 10 patients, one implant failed in one of the patient and one patient did not come for follow-up. Individuals were chosen from outpatient department of the Department of Prosthodontics, Crown and Bridge including Implantology between time period of March 2017 to March 2018. Before commencing any procedure, written consent was obtained from patients and ethical committee clearance was obtained from institutional board (Ref.no./Director-PG Studies/ITSCDSR/L/2019/096). All procedures performed in this study were in accordance with ethical standards given in 1964 Declaration of Helsinki, as revised in 2013.

### Inclusion and exclusion criteria

Inclusion criteria included individuals with maxillary and mandibular edentulous arches for more than 3 months. Moderate bone height (minimum 10 mm) and width (minimum 3.5 mm) should be present in interforaminal region. Patients with history of systemic diseases which contraindicates implant surgery were

excluded from the study. Patients with history of smoking and tobacco chewing and also with temporomandibular disorders were also excluded from study.

### Primary outcome

Primary outcome measure was to assess crestal bone loss by either of two techniques at second stage surgery, i.e., conventional and diode laser. There was no other parameter to assess.

For conducting study, mandibular complete denture was fabricated for the patient before implant placement for all patients which was duplicated in clear acrylic denture base material. Duplicated denture was perforated at canine regions, and radio-opaque material was packed in corresponding regions to be used as radiographic template [Figure 1].

### Surgical protocol

According to the Centers for Disease Control and Prevention guidelines, single dose of prophylactic antibiotic was given orally 1 h before the surgery. The radiographic template which was fabricated for making the orthopantomograph for diagnostic purpose was converted and utilized as a surgical template [Figure 2]. Implants were placed at B and D sites for all patients under local administration with lignocaine (2%) with epinephrine (1:100,000) while

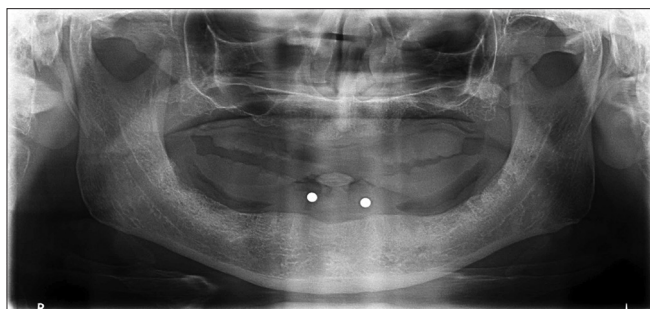
maintaining the asepsis [Figure 3]. Implant insertion tool was used for placement of implants with progressive increase in torque till 35–40 Ncm. In cases where we had to hand torque the implants, we had used manual calibrated torque gauge ratchet to insert the implants within the satisfactory torque range of 35–40 Ncm.<sup>[14]</sup> Radiograph was obtained to confirm the implant placement. Primary closure was achieved by 3-0 silk sutures and antibiotics were prescribed for the patient.

### Second-stage surgery

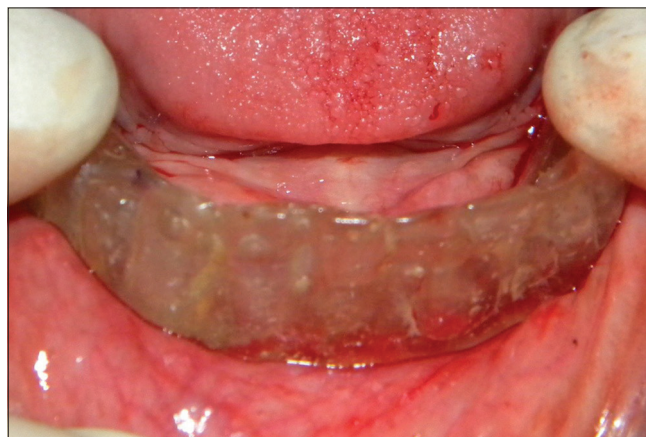At 8 weeks from implant placement, second-stage surgery was performed depending on osseointegration seen in radiograph to maintain standardization.<sup>[2]</sup> Second-stage surgery for implant which was inserted at B site was done by conventional method using scalpel blade [Figure 4a] while for D site, second-stage surgery was performed by 970 nm diode laser (ZOLAR PHOTON PLUS Dental Diode Laser, Zolar Technology and Mfg Co. Inc 6315 Shawson Drive, Unit 7-8, Mississauga On, Canada) [Figure 4b].

### Sampling of patients

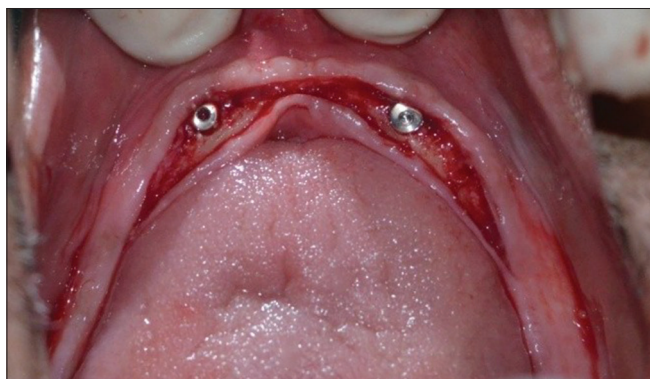Sampling of eight individuals were done on the basis of two techniques followed for second-stage surgery and individuals were divided into two groups, i.e., Group 1 – Implants exposed using scalpel at second-stage surgery and



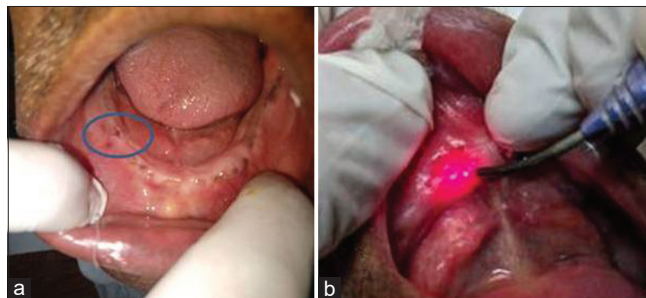**Figure 1:** Orthopantomograph with radiographic stent in canine positions



**Figure 2:** Surgical template in patient's mouth



**Figure 3:** Implants placed in B and D positions



**Figure 4:** (a) Second-stage surgery with conventional method. (b) Second-stage surgery with laser

Group 2 – implants exposed using diode laser at second-stage surgery, and further subgrouping was done on the basis of site involved, i.e., mesial, distal, labial, lingual, and method of radiographic analysis, i.e., CBCT and DR as described in flowchart [Figure 5].

**Prosthetic protocol**

Healing abutments were placed for 10 days at second-stage surgery [Figure 6a]. All patients were rehabilitated using ball and socket attachments (ADIN dental Implant System Ltd, Northern Israel). After the removal of healing abutments, the ball abutments were tightened by hand torque and torque wrench (30 Ncm) [Figure 6b]. Acrylic resin was removed from intaglio surface to allow passive fit of denture. Block out was done by using separator over the head of each ball abutment. Vent holes were prepared on the lingual aspect to remove excess resin. Pressure indicating paste (Mizzy Prestige Dental Products) was used to verify that no contact of the denture base with abutment or attachment. A No. six round bur was used to vent the pick up space toward the surface of the denture on lingual to denture teeth. The pick-up space was half filled with autopolymerizing resin (DPI-RR cold cure, Delhi) and the

mandibular denture was placed over the abutments. The complete seating of the denture was verified and the patient was asked to maintain light occlusal pressure in the centric relation position while the resin polymerizes. The pick-up resin was trimmed and polished in the venting area. Fit and occlusion of the dentures was rechecked in centric relation position [Figure 7].

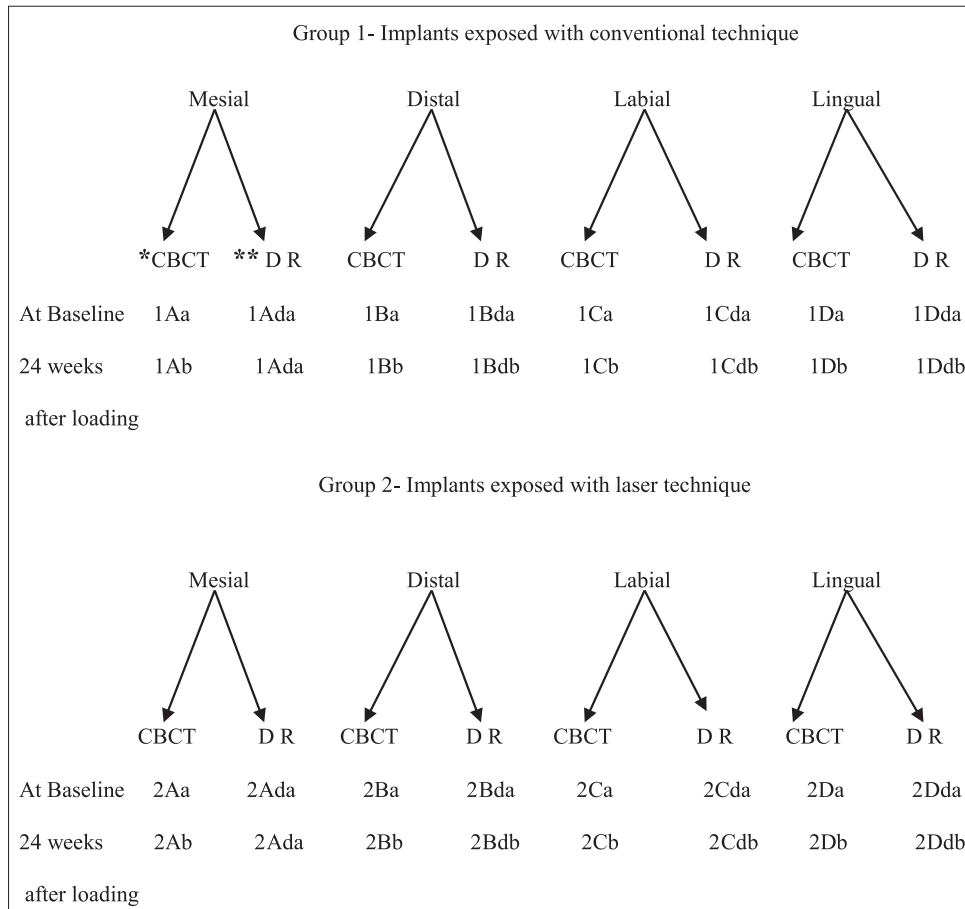
**Assessment of crestal bone levels**

Patients were subjected to radiographic analysis with CBCT and DR to evaluate crestal bone level at baseline (time of loading) and 24 weeks after loading.

**Cone beam computed tomography**

Scans were performed with standardized scanning parameters at 90 kV, 10 mA, and 3.6 s of exposure time using a field of view of 5 cm × 5 cm and a resolution of 150 μ. Interactive CBCT Processing software (NNT Version 7.0, QR srl, Italy) was used to obtain reformatted coronal, sagittal, cross-sectional, and panoramic views.

Each implant fixture was triangulated to its midpoint along its long axis in all three orthogonal planes and crestal bone



**Figure 5:** Flowchart for grouping and subgrouping of samples. \*CBCT: Cone beam computed tomography, \*\*DR: Digital radiography



height was measured to obtain 4 readings: mid-buccal, mid-lingual, mid-mesial, and mid-distal. A tangent was drawn using the drawing toolbar at the implant abutment junction. Then, using the distance toolbar, marginal bone level from the implant abutment junction to the first bone to implant contact (BIC) was measured to the nearest 100  $\mu\text{m}$  (0.1 mm). For measurements on buccal and lingual aspects, coronal reformatted views were used, and for measurements on mesial and distal aspects, sagittal reformatted views were used at baseline [Figure 8a and b] and after 24 weeks of loading for both groups [Figure 9a and b]. The triangulation protocol was standardized for each patient. Measurements were taken by an experienced oral and maxillofacial radiologist to reduce bias.

### Digital radiography

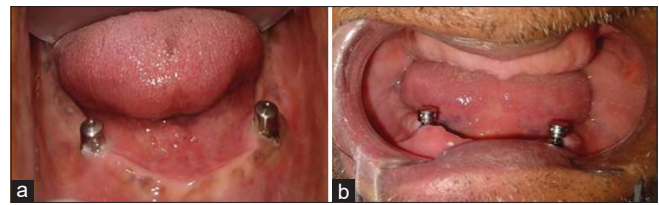
Digital intraoral periapical radiographs were performed on Photo Stimulable Plate based radiography (PSP) (Durr Dental, Germany) at the time of loading and 24 weeks after loading to assess proximal bone levels. Images were acquired using X-mind (Satelec, France) intra oral X-ray unit at 70 kV, 8 mA at 0.280 s exposure time using paralleling technique for every patient. The images were scanned using vista scan mini (Durr Dental, Germany) and imported into the DBSWIN software (Durr Dental version 5.3.1, Germany). Calibration was done according to the known implant fixture height using measurement tool of the software. A tangent was drawn at the implant abutment junction using line tool. Crestal bone levels were measured from tangent to the first BIC on both mesial and distal aspects with the help of ruler tool [Figure 10a and b]. Baseline default contrast and image brightness levels were kept as standard and were not manipulated. This measurement protocol was standardized for each patient.

### Statistical analysis

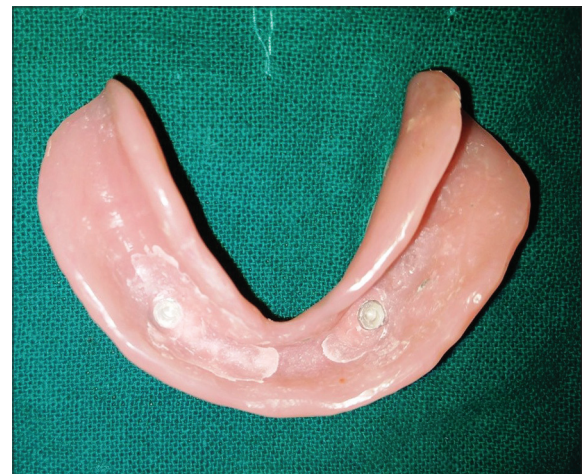The data obtained was entered into MS Excel spread sheet and analyzed, using SPSS statistical software version XXII (IBM SPSS Corp. Ltd. Armonk, NY, USA). The normality of data was checked by Shapiro–Wilk’s test. The continuous data was represented as mean  $\pm$  standard error or median (minimum–maximum). The values of the crestal bone heights (in mm) around each implants on four sites – mesial, distal, labial, lingual for CBCT scans and on two sites – mesial and distal for DR at two time intervals i.e., at loading and 24 weeks after loading was compared using test by *post hoc* comparison by Bonferroni method.  $P < 0.05$  was considered as significant.

### RESULTS

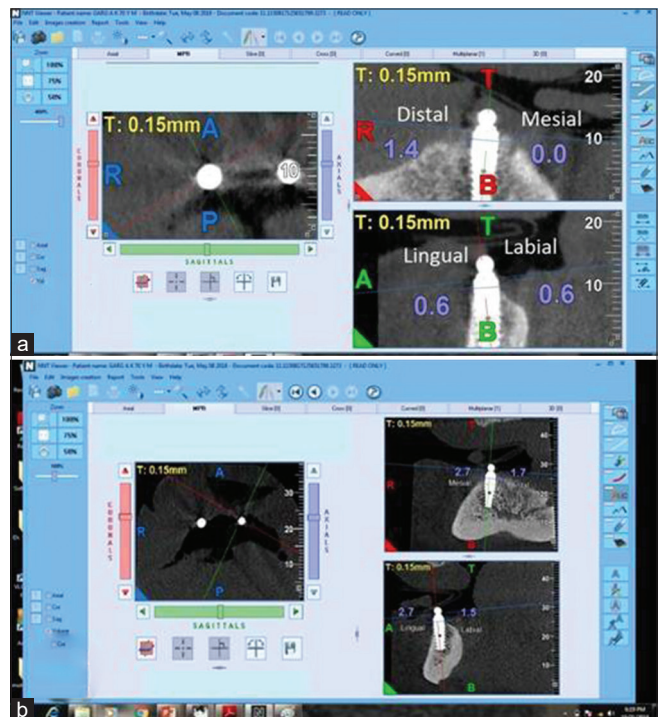
- For Groups 1Aa and 2Aa, 1Ab and 2Ab, 1ADa and 2ADa, 1ADb and 2ADb by using independent



**Figure 6:** (a) Healing abutment in place after 10 days of second-stage surgery. (b) Ball attachments in implant after removal of healing abutments



**Figure 7:** Pick-up of female housing in denture



**Figure 8:** (a) Crestal bone level for implant Group 1 by cone beam computed tomography at baseline. (b) Crestal bone level at implant Group 2 by cone beam computed tomography at baseline

*t*-test, the calculated mean difference of crestal bone levels (in mm) at baseline using CBCT ( $-0.2500$ ), and

after 24 weeks (-0.1250) which was not significant,  $P > 0.05$  [Graph 1 and Table 1]

- For same aforementioned groups, the calculated mean difference of crestal bone levels at baseline using DR (-0.0875), and after 24 weeks (-1.375) which was not significant,  $P > 0.05$  [Graph 1 and Table 1]
- For Groups 1Ba and 2Ba, 1Bb and 2Bb, 1BDa and 2BDa, 1BDb and 2BDb by using independent *t*-test, the calculated mean difference of crestal bone levels at baseline using CBCT (0.0000) and after 24 weeks (-0.2375) which was not significant,  $P > 0.05$  [Graph 2 and Table 2]
- For same aforementioned groups, the calculated mean difference of crestal bone levels at baseline using DR (-0.2250) and after 24 weeks (-0.1500)

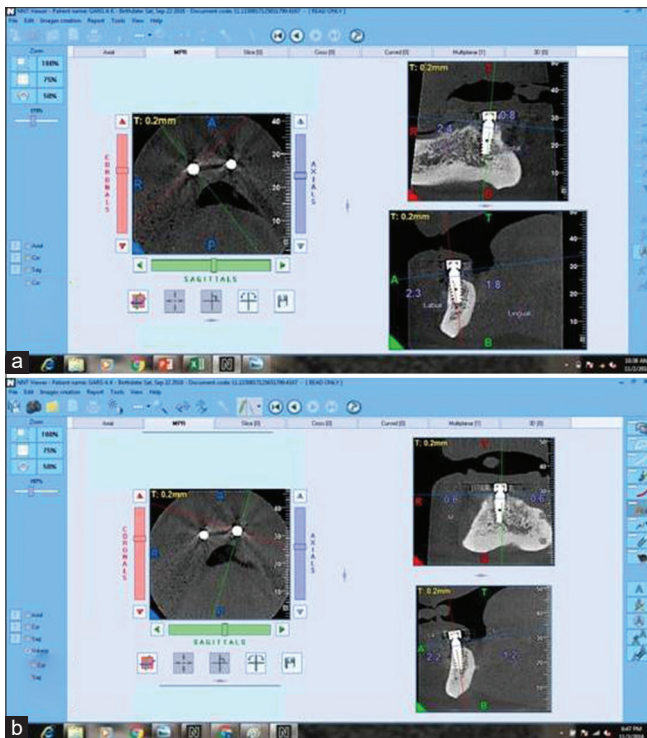
which was not significant,  $P > 0.05$  [Graph 2 and Table 2]

- For Groups 1Ca and 2Ca, 1Cb and 2Cbb by using independent *t*-test, the calculated mean difference of crestal bone levels at baseline using CBCT (0.3000) and after 24 weeks (-0.2875) which was not significant,  $P > 0.05$  [Graph 3 and Table 3]
- For Groups 1Da and 2Da, 1Db and 2Db at different time intervals using CBCT by using independent *t*-test, the calculated mean difference of crestal bone levels at baseline using CBCT (0.0250) and after 24 weeks (-0.3125) which was not significant,  $P > 0.05$  [Table 4 and Graph 4].

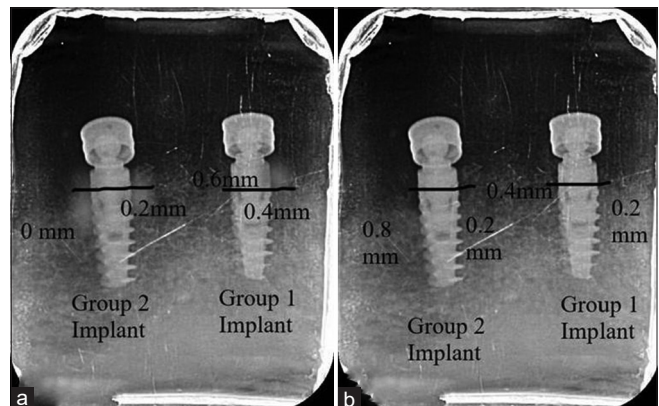
### DISCUSSION

In successfully osseointegrated endosteal implants, crestal bone loss has been considered a common phenomenon after implant placement and loading. Bone resorption is known to take place mainly during 1<sup>st</sup> year after prosthesis placement and decreasing considerably after subsequent years. Classic criteria defining implant success allowed for 1–1.5 mm of bone loss during the 1<sup>st</sup> year after loading and <0.2 mm annually thereafter.<sup>[12]</sup> Surgical trauma and healing response is one of the etiology for crestal bone loss as described by Oh *et al.*<sup>[13]</sup>

Misch recommended reflection of a full-thickness flap for second-stage surgery to identify and correct any bone



**Figure 9:** (a) Crestal bone level for implant Group 1 by cone beam computed tomography after 24 weeks of loading. (b) Crestal bone level for implant Group 2 by cone beam computed tomography after 24 weeks after loading



**Figure 10:** (a) Crestal bone level for both groups at baseline. (b) Crestal bone level for both groups after 24 weeks after loading

**Table 1: Comparison of mean of crestal bone level between Groups 1Aa and 2Aa, 1Ab and 2 Ab, 1ADa and 2ADa, 1ADb and 2ADb at different time intervals using cone beam computed tomography and digital radiography by independent *t*-test**

	Mean±SE difference	t-test for equality of means		t	df	P (two-tailed)
		95% CI of the difference				
		Lower	Upper			
CBCT baseline (at loading)	-0.2500±0.4788	-1.2770	0.7770	-0.522	14	0.610 (NS)
CBCT follow-up (24 weeks postloading)	-0.1250±0.3139	-0.7982	0.5482	-0.398	14	0.696 (NS)
Digital radiography baseline (at loading)	-0.0875±0.4208	-0.9899	0.8149	-0.208	14	0.838 (NS)
Digital radiography follow-up (24 weeks postloading)	-0.1375±0.2449	-0.6628	0.3878	-0.561	14	0.583 (NS)

CBCT: Cone beam computed tomography, CI: Confidence interval, SE: Standard error, NS: Not significant



**Table 2: Comparison of mean of crestal bone level between Group 1Ba and 2Ba, 1Bb and 2Bb, 1BDa and 2BDa, 1BDb and 2BDb at different time intervals using cone beam computed tomography and digital radiography by independent *t*-test**

	<i>t</i> -test for equality of means					
	Mean±SE difference	95% CI of the difference		<i>t</i>	df	Significant (two-tailed)
		Lower	Upper			
CBCT baseline (at loading)	0.0000±0.3868	-0.8296	0.8296	0.000	14	1.000
CBCT follow-up (24 weeks postloading)	0.2375±0.3583	-0.5310	1.0060	0.663	14	0.518
Digital radiography baseline (at loading)	-0.2250±0.3549	-0.9863	0.5363	-0.634	14	0.536
Digital radiography follow-up (24 weeks postloading)	-0.1500±0.3461	-0.8923	0.5923	-0.433	14	0.671

CBCT: Cone beam computed tomography, CI: Confidence interval, SE: Standard error

**Table 3: Comparison of mean of crestal bone level between Group 1Ca and 2Ca, 1Cb and 2Cb at different time intervals using cone beam computed tomography by independent *t*-test**

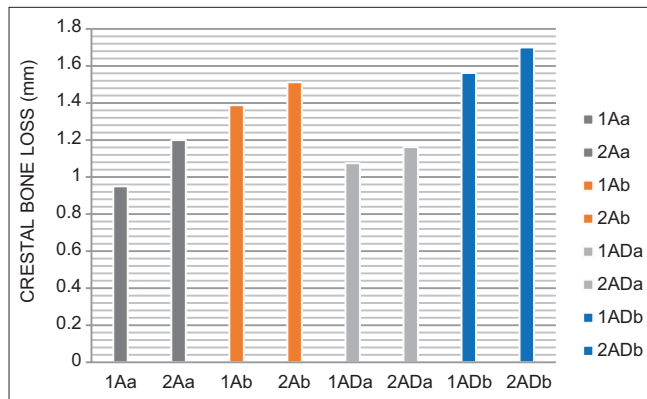
	<i>t</i> -test for equality of means					
	Mean ± SE difference	95% CI of the difference		<i>t</i>	df	Significant (two-tailed)
		Lower	Upper			
CBCT baseline (at loading)	0.3000 ± 0.4474	-0.6596	1.2596	0.671	14	0.513
CBCT follow-up (24 weeks postloading)	-0.2875 ± 0.3809	-1.1044	0.5294	-0.755	14	0.463

CBCT: Cone beam computed tomography, CI: Confidence interval, SE: Standard error

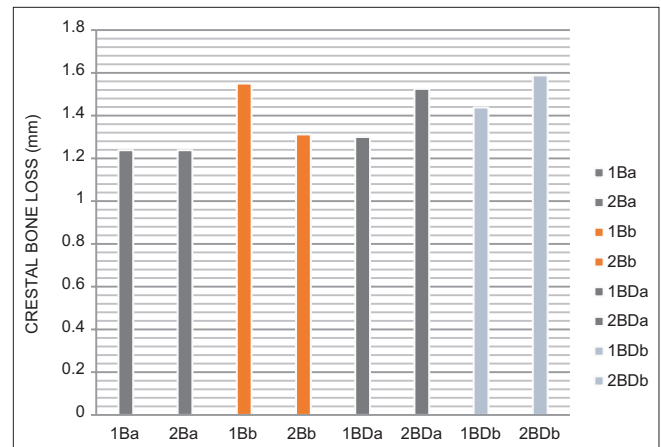
**Table 4: Comparison of mean of crestal bone level between Groups 1Da and 2Da, 1Db and 2Db at different time intervals using cone beam computed tomography by independent *t*-test**

	<i>t</i> -test for equality of means					
	Mean±SE difference	95% CI of the difference		<i>t</i>	df	<i>P</i> (two-tailed)
		Lower	Upper			
CBCT baseline (at loading)	0.0250±0.3746	-0.7784	0.8284	0.067	14	0.948
CBCT follow-up (24 weeks postloading)	-0.3125±0.3648	-1.0950	0.4700	-0.857	14	0.406

CBCT: Cone beam computed tomography, CI: Confidence interval, SE: Standard error



**Graph 1:** Distribution of mean of crestal bone level of Groups 1Aa and 2Aa, 1Ab and 2Ab, 1ADa and 2ADa, 1ADb and 2ADb at different time intervals using cone beam computed tomography and digital radiography

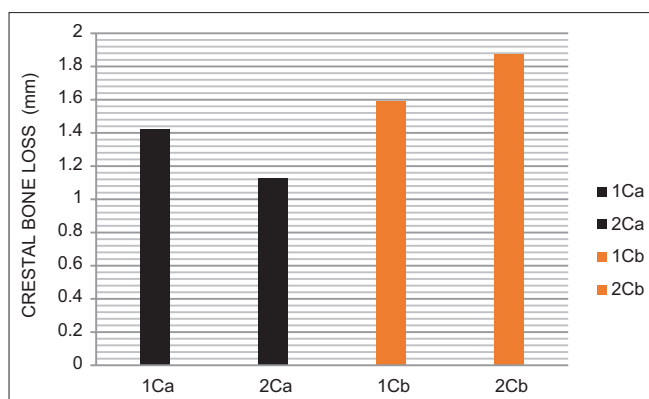


**Graph 2:** Distribution of mean of crestal bone level of Group 1Ba and 2Ba, 1Bb and 2Bb, 1BDa and 2BDa, 1BDb and 2BDb at different time intervals using cone beam computed tomography and digital radiography

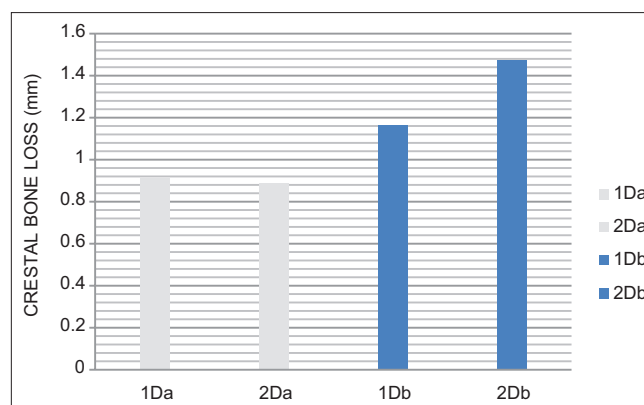
defects around an implant, to reposition keratinized tissue, and to decrease the amount of thick mucosa. Radiographs are used to closely evaluate the crestal, mesial, and distal bone–implant interfaces before the second-stage uncovering procedure. In animal and clinical studies, there was little or no crestal bone loss identified at second stage uncovering after the mini-incision submerged procedure indeed, there were no bony defects around the mini-incision submerged implants that required treatment. Therefore, there is no need to reflect a mucoperiosteal flap in order

to identify a defect after the mini incision submerged procedure. It should be noted that additional surgery can lead to additional bone loss when a full-thickness flap is reflected.<sup>[14]</sup>

Fickl *et al.* histologically assessed whether elevation of partial-thickness flaps results in reduced bone alterations, as compared with full-thickness flap preparations. They investigated osteoclastic activity in both flap procedures,



**Graph 3:** Distribution of mean of crestal bone level of Groups 1Ca and 2Ca, 1Cb and 2Cb at different time intervals using cone beam computed tomography



**Graph 4:** Comparison of mean of crestal bone level between Groups 1Da and 2Da, 1Db and 2Db at different time intervals using cone beam computed tomography by independent t-test

however less osteoclastic activity was found with split-flap technique.<sup>[8]</sup>

One of the most interesting uses of lasers in implant dentistry is when lasers are used for uncovering in second-stage implant surgery providing less postoperative pain, less bleeding, and faster healing.<sup>[15]</sup> There was a concern in the past about using lasers around dental implant as it may damage the topography of the implant surface. Kreisler *et al.* compared the effects of various laser wavelengths on titanium implants and he concluded that neodymium-doped yttrium aluminum garnet (YAG) and holmium:YAG lasers are contraindicated on osseointegrated implant surface irrespective of power output, the erbium-doped YAG and CO<sub>2</sub> output powers must be limited to avoid implant damaging while Gallium-Aluminum-Arsenide are safely used as no structural damage to the implant surface was occurred after laser irradiation.<sup>[16]</sup> The ability of the diode laser not to affect either polished titanium or SLA disks was confirmed by Stubinger *et al.*<sup>[17]</sup>

El-Kholey advocated the use of diode laser in second-stage implant surgery and suggested that it can minimize surgical trauma, eliminate the need for anesthesia, improve visibility during surgery due to the absence of bleeding, and eliminate postoperative discomfort. However there was no difference in success of implant.<sup>[18]</sup>

Based on these studies, it can be assumed that laser and specifically diode laser at wavelength of 970 nm can be safely used to uncover the implant at second-stage surgery, and it is known to cause lesser trauma, and in turn lesser bone loss and promote healing around the implant and thus we used a diode laser at 970 nm in our study.

CBCT imaging finds application in presurgical imaging, as well as surgical – intraoperative and postsurgical

evaluation.<sup>[19]</sup> Dreiseidler *et al.* have investigated and analyzed the accuracy of peri-implant bone evaluation using CBCT, digital intra-oral radiographs and histology.<sup>[20]</sup> Their study wraps up the conclusion stating that three-dimensional CBCT provides usable information about bone in all dimensions around implants with varying accuracy. Based on the aforementioned study we adopted two methods of evaluation of crestal bone levels to make out if there exists a co-relation between these two methods on the sidelines of our primary study. In our study, a threaded collar implant was chosen over a smooth collar because the latter may contribute to more bone loss.<sup>[21]</sup>

Within the limitations of present study, we adjudge no significant difference in crestal bone levels following different procedures for second-stage surgery. Lesser bone loss was expected with laser based approach but on the contrary though insignificant, our study indicates slightly more bone loss with the use of diode laser over scalpel. The contradict results may be due to power used with laser and also laser was used without air cooling. In a study by Leja *et al.*, he reported that during implant radiation using a diode laser with a 980 nm wavelength and at average power of 1 W without air-cooling, implant overheating occurred considerably in comparison with power of 2 W.<sup>[22]</sup> Therefore, for safety reasons, the average power of the laser radiation must be reduced during implant uncovering without air-cooling, but lowering the average laser power extends the duration of the surgical procedure. In another study by Geminiani *et al.*, it was observed that with diode laser of 810 nm there is 10°C increase of temperature in 14 s as compared to laser with 980 nm, in which there is increase in temperature within 12 s.<sup>[23]</sup>

According to the results obtained in present study, there is insignificant difference in crestal bone loss by either technique of second-stage surgery. The decision to choose



one second-stage surgery technique over other is mainly influenced by the choice of the operator and patient comfort. Further studies are required to decide upon and reaffirm that which technique surpasses the other one and is scientifically validated to be better for the patient who is the ultimate beneficiary.

## CONCLUSIONS

Within the limitations of the study, the following conclusions were drawn:

1. CBCT analysis performed at baseline showed slightly more bone loss in diode laser group at mesial side compared to conventional scalpel group whereas distal side showed no difference at all in either of the groups whereas there was no significant difference around labial and lingual sites
2. CBCT analysis performed 24 weeks after loading showed slightly more bone loss in diode laser group for mesial sites compared to conventional scalpel group whereas distal site showed slightly lesser bone loss for laser exposed sites. On labial site, laser exposed sites had shown slightly more bone loss than conventional sites and lingual sites revealed marginally more bone loss for conventional surgical exposures
3. Digital radiographic analysis at baseline showed slightly more bone loss in diode laser group at mesial side compared to conventional group whereas distal side showed more crestal bone loss for laser exposed site than conventionally scalpel exposed site. Follow-up evaluations showed similar results on mesial sites and distal sites.

## Declaration of patient consent

The authors certify that they have obtained all appropriate patient consent forms. In the form, the patients have given their consent for their images and other clinical information to be reported in the journal. The patients understand that their names and initials will not be published and due efforts will be made to conceal their identity, but anonymity cannot be guaranteed.

## Financial support and sponsorship

Nil.

## Conflicts of interest

There are no conflicts of interest.

## REFERENCES

1. Misch CE. Contemporary Implant Dentistry. 2<sup>nd</sup> ed. Mosby Co: St. Louis; 1999. p. 1-17.
2. Schimmel M, Srinivasan M, Herrmann FR, Müller F. Loading protocols for implant-supported overdentures in the edentulous jaw:

- A systematic review and meta-analysis. *Int J Oral Maxillofac Implants* 2014;29 Suppl:271-86.
3. Feine JS, Carlsson GE, Awad MA, Chehade A, Duncan WJ, Gizani S, *et al.* The McGill consensus statement on overdentures. Mandibular two-implant overdentures as first choice standard of care for edentulous patients. *Gerodontology* 2002;19:3-4.
4. Bhat S, Chowdhary R, Mahoorkar S. Comparison of masticatory efficiency, patient satisfaction for single, two, and three implants supported overdenture in the same patient: A pilot study. *J Indian Prosthodont Soc* 2016;16:182-6.
5. Singh P, Garge HG, Parmar SV, Viswambaran M, Goswami MM. Evaluation of implant stability and crestal bone loss around the implant prior to prosthetic loading: A six month study. *J Ind Prosthodont Soc* 2006;6:33-7.
6. Suchetha A, Phadke PV, Sapna N, Rajeshwari HR. Optimising esthetics in second stage dental implant surgery: Periodontist's ingenuity. *J Dent Implant* 2014;4:170-5.
7. Hildebolt CF, Couture R, Garcia NM, Dixon D, Miley DD, Shannon W, *et al.* Alveolar bone measurement precision for phosphor-plate images. *Oral Surg Oral Med Oral Pathol Oral Radiol Endod* 2009;108:e96-107.
8. Fickl S, Kebschull M, Schupbach P, Zuhr O, Schlagenhauf U, Hürzeler MB. Bone loss after full-thickness and partial-thickness flap elevation. *J Clin Periodontol* 2011;38:157-62.
9. Fasbinder DJ. Dental laser technology. *Compend Contin Educ Dent* 2008;29:452-4, 456, 458-9.
10. Convissar A. Principles and Practice of Laser Dentistry. 1<sup>st</sup> ed. St. Louis, missouri: Mosby, Elsevier; 2011. p. 114-38.
11. Cehreli MC, Karasoy D, Akca K, Eckert SE. Meta-analysis of methods used to assess implant stability. *Int J Oral Maxillofac Implants* 2009;24:1015-32.
12. Smith DE, Zarb GA. Criteria for success of osseointegrated endosseous implants. *J Prosthet Dent* 1989;62:567-72.
13. Oh TJ, Yoon J, Misch CE, Wang HL. The causes of early implant bone loss: Myth or science? *J Periodontol* 2002;73:322-33.
14. Misch CE. Contemporary Implant Dentistry. 3<sup>rd</sup> ed. St. Louis: Mosby Co.; 2008. p. 975-1012.
15. Martin E. Lasers in dental implantology. *Dent Clin North Am* 2004;48:999-1015, viii.
16. Kreisler M, Götz H, Duschner H. Effect of Nd: YAG, Ho: YAG, Er: YAG, CO<sub>2</sub>, and GaAIs laser irradiation on surface properties of endosseous dental implants. *Int J Oral Maxillofac Implants* 2002;17:202-11.
17. Stubinger S, Etter C, Miskiewicz M, Homann F, Saldamli B, Wieland M, *et al.* Surface alterations of polished and sandblasted and acid-etched titanium implants after Er: YAG, carbon dioxide, and diode laser irradiation. *Int J Oral Maxillofac Implants* 2010;25:104-11.
18. El-Kholey KE. Efficacy and safety of a diode laser in second-stage implant surgery: A comparative study. *Int J Oral Maxillofac Surg* 2014;43:633-8.
19. John PG, Joy ET, Mathew J, Kumar RB. Application of cone beam computed tomography for a prosthodontist. *J Ind Prosthodont Soc* 2016;16:3-7.
20. Dreiseidler T, Mischkowski RA, Neugebauer J, Ritter L, Zöller JE. Comparison of cone-beam imaging with orthopantomography and computerized tomography for assessment in presurgical implant dentistry. *Int J Oral Maxillofac Implants* 2009;24:216-25.
21. Misch CE, Bidez MW. A scientific rationale for dental implant design. In: Misch CE, editor. Contemporary Implant Dentistry. 3<sup>rd</sup> ed. St. Louis: Mosby; 2008. p. 200-29.
22. Leja C, Geminiani A, Caton J, Romanos GE. Thermodynamic effects of laser irradiation of implants placed in bone: An *in vitro* study. *Lasers Med Sci* 2013;28:1435-40.
23. Geminiani A, Caton JG, Romanos GE. Temperature change during non-contact diode laser irradiation of implant surfaces. *Lasers Med Sci* 2012;27:339-42.